



## Case Report

# SARS-CoV-2 precipitated Kasabach-Merritt syndrome in a child with angioma infantile and acute lymphoblastic leukemia: Case Report

## Síndrome de Kasabach-Merritt precipitado por SARS-CoV-2 en un niño con angioma infantil y leucemia linfoblástica aguda: Reporte de Caso

DOI

Vanessa Zarate<sup>1,a</sup>, Alejandra Cahuata<sup>1,a</sup>, Roxana Díaz<sup>1,a</sup>, Giancarlo Alvarado-Gamarra<sup>1,a</sup>, Kenny Chonlon<sup>1,b</sup>, Jesús Ángel Domínguez-Rojas<sup>1,2,b</sup>

<https://doi.org/10.35434/rcmhnaaa.2021.143.1278>

### ABSTRACT

**Background:** We describe an 8-month-old boy with leukemia and SARS-CoV-2 infection who developed Kasabach-Merritt phenomenon. He had a positive SARS-CoV-2 RT-PCR sample. Hematologic tests showed coagulopathy and intestinal involvement. She was managed in emergency receiving transfusion support and in hospitalization with social isolation measures, she started propranolol and corticotherapy as initial treatment of infantile angiomas. She presented with symptoms of intestinal obstruction and underwent surgery and evidence of hemorrhagic infarction with foci of intestinal ischemic necrosis, ending in ileostomy. We tried to understand a pathophysiological explanation of the dermatologic and gastrointestinal tract involvement by the virus and the atypical form of COVID-19. Given the emerging evidence of endothelial and vascular involvement in COVID-19, the development of tests to detect vascular lesions may be critical to guide the use of new therapeutic strategies.

**Keywords:** Kasabach-Merritt Syndrome; Child; Pediatrics; SARS-CoV-2 (Source: DeCS-BIREME).

### RESUMEN

**Introducción:** Describimos a un niño de 8 meses con leucemia e infección por SARS-CoV-2 que desarrolló el fenómeno de Kasabach-Merritt. Tenía una muestra de RT-PCR de SARS-CoV-2 positiva. Las pruebas hematológicas mostraron coagulopatía y afectación intestinal. Fue manejada en emergencia recibiendo apoyo transfusional y en hospitalización con medidas de aislamiento social, inició propranolol y corticoterapia como tratamiento inicial de los angiomas infantiles. Presentó síntomas de obstrucción intestinal y fue intervenida quirúrgicamente y se evidenció infarto hemorrágico con focos de necrosis isquémica intestinal, terminando en ileostomía. Intentamos comprender una explicación fisiopatológica de la afectación dermatológica y del tracto gastrointestinal por el virus y la forma atípica de

### FILIATION

1. Departamento de Pediatría Clínica, Hospital Edgardo Rebagliati Martins, Lima, Perú.
2. La Red Network, Universidad Nacional Federico Villarreal, Lima, Perú.
  - a. Médico Pediatra
  - b. Médico Pediatra Internista.

### ORCID

1. Vanessa Zarate / [0000-0001-5839-9673](https://orcid.org/0000-0001-5839-9673)
2. Alejandra Cahuata / [0000-0002-1421-7441](https://orcid.org/0000-0002-1421-7441)
3. Roxana Díaz / [0000-0002-6408-9935](https://orcid.org/0000-0002-6408-9935)
4. Giancarlo Alvarado-Gamarra / [0000-0002-7266-5808](https://orcid.org/0000-0002-7266-5808)
5. Kenny Chonlon / [0000-0002-6813-2902](https://orcid.org/0000-0002-6813-2902)
6. Jesús Ángel Domínguez-Rojas / [0000-0001-6141-6622](https://orcid.org/0000-0001-6141-6622)

### CORRESPONDENCE

Dr. Jesús Ángel Domínguez Rojas, Departamento de Pediatría, Hospital Edgardo Rebagliati Martins, Fray Angélico 238 Dpto 103, San Borja, Lima, Perú, Tel.: +51953907559

### EMAIL

[jesusdominguez24@gmail.com](mailto:jesusdominguez24@gmail.com)

### CONFLICTS OF INTEREST

The authors of this manuscript certify that they have no affiliations with or involvement in any organization or entity with any financial interest (such as honoraria; educational grants; participation in speakers' bureaus; membership, employment, consultancies, stock ownership, or other equity interest; and expert testimony or patent/licensing arrangements) or nonfinancial interest (such as personal or professional relationships, affiliations, knowledge or beliefs) in the subject matter or materials discussed in this manuscript.

### FINANCING

Self-financing.

### AUTHOR CONTRIBUTIONS

All persons who meet authorship criteria are listed as authors, and all authors certify that they have participated sufficiently in the work to take public responsibility for the content, including participation in the concept, design, analysis, writing, or revision of the manuscript.

### CONSENT TO PARTICIPATE

The authors of this manuscript certify that informed consent was obtained and signed from the patient's parent/legal guardian to participate in this case report for submission to the journal.

### CONSENT TO PUBLISH

The authors of this manuscript certify that informed consent was obtained and signed from the participant's parent/legal guardian regarding publishing their data and photographs.

### PEER REVIEW

Received: 06/09/2021  
Accepted: 10/10/2021

### HOW TO CITE

Zarate, V., Cahuata, A., Díaz, R., Alvarado-Gamarra, G., Chonlon, K., & Domínguez-Rojas, J. Síndrome de Kasabach-Merritt precipitado por SARS-CoV-2 en un niño con angioma infantil y leucemia linfoblástica aguda: Reporte de Caso. Revista Del Cuerpo Médico Hospital Nacional Almanzor Aguinaga Asenjo, 2021, 14 (3), 387 - 389. <https://doi.org/10.35434/rcmhnaaa.2021.143.1278>



This work is under a Licencia Creative Commons Atribución 4.0 Internacional.  
Printer Version: ISSN: 2225-5109  
Electronic Version: ISSN: 2227-4731  
Cross Ref. DOI: 10.35434/rcmhnaaa  
OJS: <https://cmhnaaa.org.pe/ojs>

COVID-19. Dada la evidencia emergente de la afectación endotelial y vascular en COVID-19, el desarrollo de pruebas para detectar lesiones vasculares puede ser crítico para guiar el uso de nuevas estrategias terapéuticas.

**Palabras Clave:** Síndrome de Kasabach-Merritt; Niño; Pediatría; SARS-CoV-2 (Fuente: DeCS-BIREME).

## INTRODUCTION

The association between giant hemangioma and thrombocytopenia was described by Haig Kasabach and Katharine Merritt in 1940<sup>(1)</sup>. Kasabach Merritt syndrome is usually a rapidly growing vascular anomaly causing consuming coagulopathy, thrombocytopenia, hypofibrinogenemia, Dimer d high, microangiopathic hemolytic anemia, prolonged prothrombin time and partial thromboplastin time; this syndrome is 90% associated with Kaposiform Hemangioendothelioma<sup>(2,3)</sup>. KHE has an unpredictable course and with visceral infiltration are considered extensive and unresectable lesions, so they have a poor prognosis<sup>(4)</sup>.

## CASE PRESENTATION

An 8-month-old boy with debut of acute lymphoblastic leukemia and angioma infantile who presented with Kasabach Merritt syndrome precipitated by SARS-CoV-2 infection. According to the mother, 5 days ago he presented fever, rhinorrhea and describes a violaceous lesion in the right dorsal region. RNA testing for SARS coronavirus 2 was performed on a respiratory specimen by RT-PCR and was positive. A 6 x 7 cm diameter, indurated, purplish-red lesion with superficial telangiectasias was observed [Figure 1]. Thoracic angiography showed vascular pedicle in the dorsal trajectory related to vascular structures branches of the intercostal 11 and 12 without organ involvement [Figure 2]. Blood tests on the fifth day show severe thrombocytopenia 7000/mm<sup>3</sup> (150000- 400000/mm<sup>3</sup>), leukopenia 1740/mm<sup>3</sup> (5000-14500/mm<sup>3</sup>), and severe neutropenia 130/mm<sup>3</sup> (1800-8000/mm<sup>3</sup>), positive C-reactive protein 24.9 mg/dl (0-1mg/dl) and hypoalbuminemia 2.89 g/dl (3,2-4,8g/dl), elevated prothrombin time 103.48 sec (10,5-17 sec), INR 11.45, d-dimer 15.4 ug/ml (0-0,54 ug/ml), partial thromboplastin time and undetectable fibrinogen (200-400 mg/dl), ferritin 561.3 ng/ml (28-365 ng/ml), receiving platelet transfusions, cryoprecipitate, propranolol and methylprednisolone. Prior to the start of treatment with propranolol, a cardiological evaluation was performed. Propranolol was used according to the initial management of infantile angiomas, and corticosteroids in case of suspected kaposiform hemangioma, with transient improvement. After two weeks of hospitalization he presented vomiting, abdominal distension, painful abdomen on palpation, with suspicion of intestinal obstruction and underwent surgery, presenting abdominal perforation and ending with functional ileostomy. The biopsy of the intestinal segment described hemorrhagic infarction lesions with foci of ischemic necrosis, without evidence of thrombi.

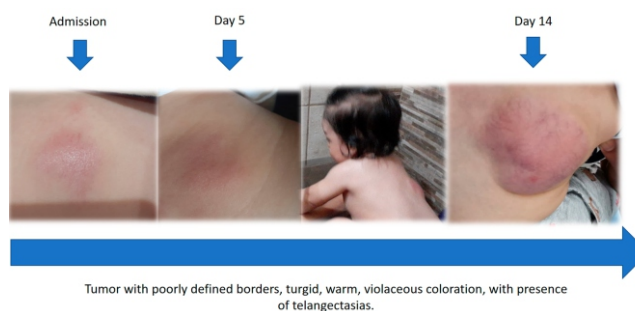


Figure 1. Evolving dermatological images of the vascular lesion

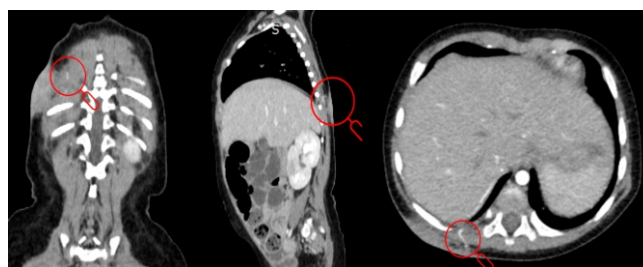


Figure 2. Thoracic Tomography

The images describe a soft tissue lesion in the lower right posterolateral thoracic wall measuring 11mm thick and 5.9 cm in greatest diameter, related to vascular structures of the intercostal branches 11 and 12 on the same side, best represented in arterial phase.

## DISCUSSION

The wide range of underlying causes and mechanisms of cutaneous involvement in viral infections justifies that SARS-CoV-2 infection may trigger cutaneous or vascular alterations.

The mechanisms of vascular injury in COVID-19 appear to be related to inflammation, endothelial injury and thrombosis<sup>(5)</sup>. Above all, increased immune responses and cytokine storms cause thrombotic disorders in patients with severe COVID-19, with high levels of d-dimer being found in most patients with COVID-19<sup>(6,7)</sup>.

SARS-CoV-2 infection may be a precipitating factor of Kasabach-Merritt phenomenon and intestinal coagulopathies.

It should be reported that the observed vascular cutaneous manifestations, should also pay attention in predicting the prognosis of patients with COVID - 19 [8]. Treatment of KM is supportive and prevention of life-threatening complications while addressing the underlying tumor<sup>(9)</sup>. This condition caused by COVID-19 focuses on gastrointestinal decompression, fluid resuscitation, hemodynamic support, surgical resection of necrotic bowel, and restoration of blood flow to the ischemic bowel<sup>(10)</sup>.

## CONCLUSIONS

SARS-CoV-2 in children with cancer can precipitate the formation of giant vascular lesions with Kasabach-Merritt phenomenon. Coagulopathy caused by SARS-CoV-2 exposure requires evaluation of all organs at risk for thrombosis. SARS-CoV-2 in children with comorbidities may pose a critical risk, including admission to a pediatric intensive care unit.

## BIBLIOGRAPHIC REFERENCES

1. HH K, KK M. Capillary hemangioma with extensive purpura: Report of a case. *Am J Dis Child*. 1940 May 1;59(5):1063-70.
2. Wang P, Zhou W, Tao L, Zhao N, Chen X-W. Clinical analysis of kasabach-merritt syndrome in 17 neonates. *BMC Pediatr*. 2014 Jun 11;14:146.
3. Acharya S, Pillai K, Francis A, Criton S, Parvathi VK. Kasabach merritt syndrome: management with interferon. *Indian J Dermatol*. 2010;55(3):281-3.
4. Drolet BA, Trenor CC, Brandão LR, Chiu YE, Chun RH, Dasgupta R, et al. Consensus-derived practice standards plan for complicated Kaposiform hemangioendothelioma. *J Pediatr*. 2013;163(1):28591.
5. Roumen - Klappe EM, den Heijer M, van Uum SH, et al. Respuesta inflamatoria en la fase aguda de la trombosis venosa profunda . *J Vasc Surg* . 2002; 35 ( 4 ): 701-706.
6. José RJ, Manuel A. Tormenta de citocinas COVID-19: la interacción entre la inflamación y la coagulación. *Lancet Respir Med*. 2020; 8 (6): e46 - e47.
7. Zhou F, Yu T, Du R y col. Curso clínico y factores de riesgo para la mortalidad de adultos en pacientes con COVID-19 en Wuhan, China: un estudio de cohorte retrospectivo. *Lancet*. 2020; 395 (10229): 1054-1062.
8. Afsaneh Sadeghzadeh-Bazargan MD, Mahdi Rezai MD. Skin manifestations as potential symptoms of diffuse vascular injury in critical COVID-19 patients. *J Cutan Pathol*. 15 de junio de 2021: 10.1111 / cup.14059.
9. Priya Mahajan, Judith Margolin. Kasabach-Merritt Phenomenon: Classic Presentation and Management Options. *Clin Med Insights Blood Disord*. 2017 Mar 16; doi:10.1177/1179545X17699849.
10. Balraj Singh, Ashesha Mechineni. Acute Intestinal Ischemia in a Patient with COVID-19 Infection. *Korean J Gastroenterol* 2020; 76(3): 164-166. <https://doi.org/10.4166/kjg.2020.76.3.164>.